0008-3194/2003/110–115/$2.00/©JCCA 2003

Thoracic spine compression fractures following a snowboarding accident: a case study

Natalia Lishchyna, BSc, DC*
Rahim Karim, BSc, DC,* FCCRS(C), DACRB

This case deals with thoracic compression fractures in a young adult following a snowboarding accident. These fractures are generally considered stable and are treated conservatively. Assessment, diagnosis, radiographic appearances, passive and active treatment protocols and prognosis are reviewed. Whenever significant trauma is involved, the chiropractor must suspect a fracture as a differential diagnosis.
(JCCA 2003; 47(2):110–115)

KEY WORDS: spinal compression fracture, thoracic spine fracture, vertebrae, snowboarding accidents, chiropractic, rehabilitation.

Ce cas aborde les fractures par tassement thoracique chez de jeunes adultes suite à un accident de planche à neige. Ces fractures sont généralement considérées stables et traitées de manière conventionnelle. L'évaluation, le diagnostic, les radiographies, les protocoles de traitement actifs et passifs et le pronostic sont examinés. Chaque fois qu'il est en présence d'un trauma significatif, le chiropracteur doit soupçonner une fracture comme diagnostic différentiel.
(JACC 2003; 47(2):110–115)

MOTS CLÉS : fracture par tassement spinal, fracture de la colonne thoracique, vertèbre, accidents de planche à neige, chiropractie, réadaptation

Introduction

Snowboarding has become a popular sport in recent years, particularly for young adults.[1,2] Unfortunately, the rate of spinal injuries has also risen. Spinal injuries can range from minor, including sprains and strains, to more severe, such as fractures and neurological compromise. Spinal fractures related to sport injuries most commonly involve the cervical or lumbar spine due to increased mobility in these anatomical regions.[3] Although the thoracic spine is considered to be at a lower risk due to the supporting adjacent ribs, the possibility of thoracic fractures should be considered as a differential diagnosis when a patient presents with back pain.[3,4]

The following case describes compression fractures at the middle to lower thoracic spine in a young adult male. The patient was initially misdiagnosed in the hospital emergency room and was treated for thoracic back strain. He subsequently consulted a chiropractor for his neck and mid-back discomfort. The characteristic presentation, appropriate examination and rehabilitation of the patient are discussed.

Case

A 23-year-old male fell backward from an intentional jump while snowboarding. He lost consciousness for approximately fifteen minutes (reported by friends). He was transported by ambulance to a local hospital. In the emergency room he had x-rays taken of his chest, ribs and thoracic spine. The radiographs were read as normal. He was admitted over night for observation and discharged

* Canadian Memorial Chiropractic College.
Address correspondence to: Dr. Natalia Lishchyna, 1900 Bayview Avenue, Toronto, Ontario M4G 3E6. Tel: 416-482-2340 ext 598.

the next morning with a prescription for Tylenol #2 for his aches and pains.

Two days later he consulted a chiropractor for his neck stiffness/tightness and severe pain in the mid-back and left anterior rib cage. He described the mid-back and rib pain to be sharp and stabbing, and complained of shortness of breath. He indicated that the pain was worsened with deep breathing, coughing, standing and sitting.

The patient denied having any radiation of numbness or paraesthesia into the upper or lower extremities. He denied having any memory loss, blurring of vision, nausea, dizziness or headaches. The patient reported an unremarkable past medical health history. He indicated that he was a smoker and occasionally consumed alcohol.

Examination findings revealed a tall, slender male in considerable distress. He had a flexed forward antalgic posture and clenched his left anterior rib cage with his right arm. Postural exam revealed a flattened thoracic kyphosis with mild anterior head carriage.

Neurological screen for sensation, strength, and deep tendon reflexes in the upper and lower extremities was within normal limits. Cranial nerves (2–12) tested were unremarkable.

Active and passive cervical ranges of motion were limited globally by 25% with reported diffuse pain in the cervical spine. Thoracic active and passive ranges of motion were severely limited in all planes with reported marked tenderness. The patient was very hesitant to lie supine or prone due to provocation of severe pain in the mid/lower thoracic area.

Valsalva maneuver elicited pain in the mid/lower thoracic region. Posterior joint provocation tests elicited pain at C6 and T5–9. Manual palpation produced marked tenderness in the mid to lower thoracic region. Rib palpation was very tender for the mid to lower thoracic region and for the mid to lower anterior rib cage. Motion palpation revealed restrictions at C6 and T5–9 segments. Muscle palpation demonstrated tenderness and hypertonicity of the cervical and thoracic paraspinal, scalene, sternocleidomastoid, trapezius, quadratus lumborum and intercostal musculature.

The patient was suspected of having thoracic spine and/or rib fractures as a result of the recent trauma. He was referred to a medical radiology facility for radiographs. The radiology report stated that there was an anterior wedge deformity of the T7 and T8 vertebral bodies with a

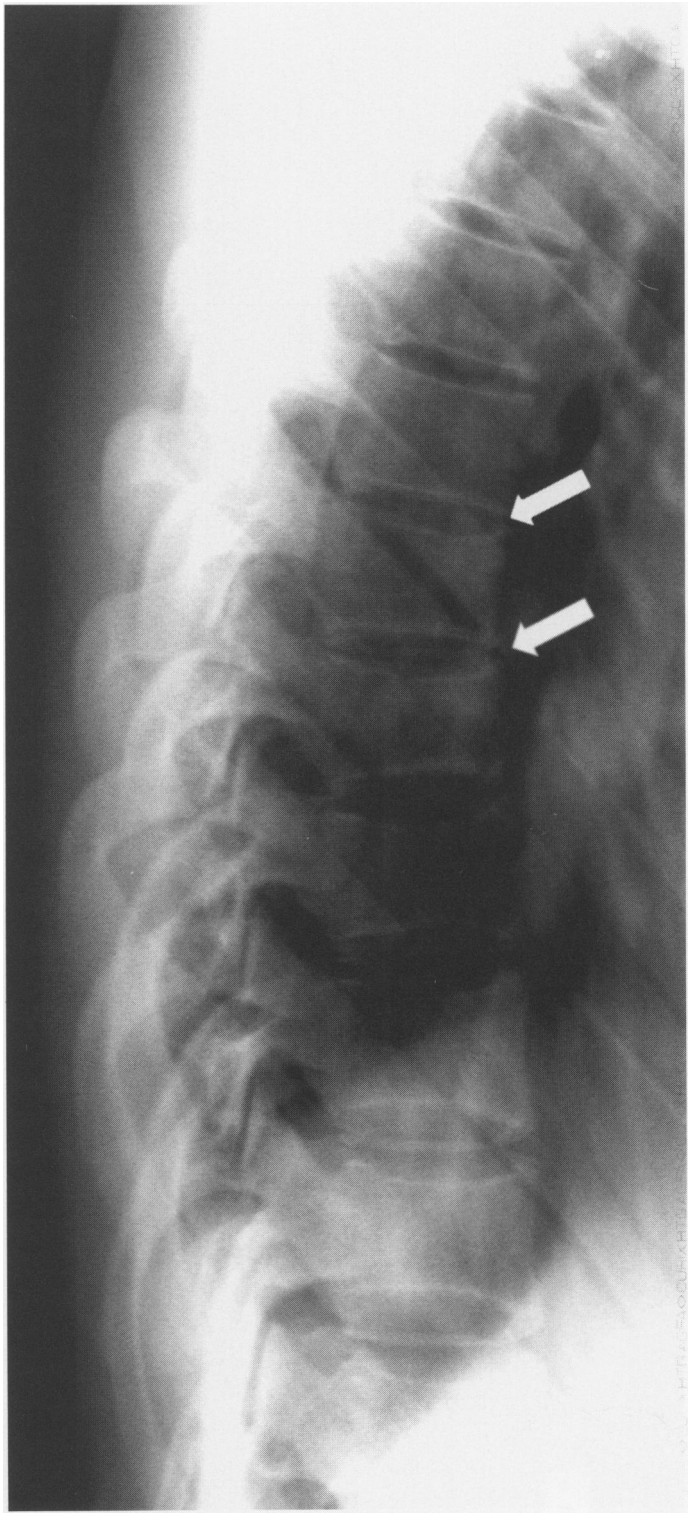

Figure 1 Anterior wedge deformity T7 and T8.

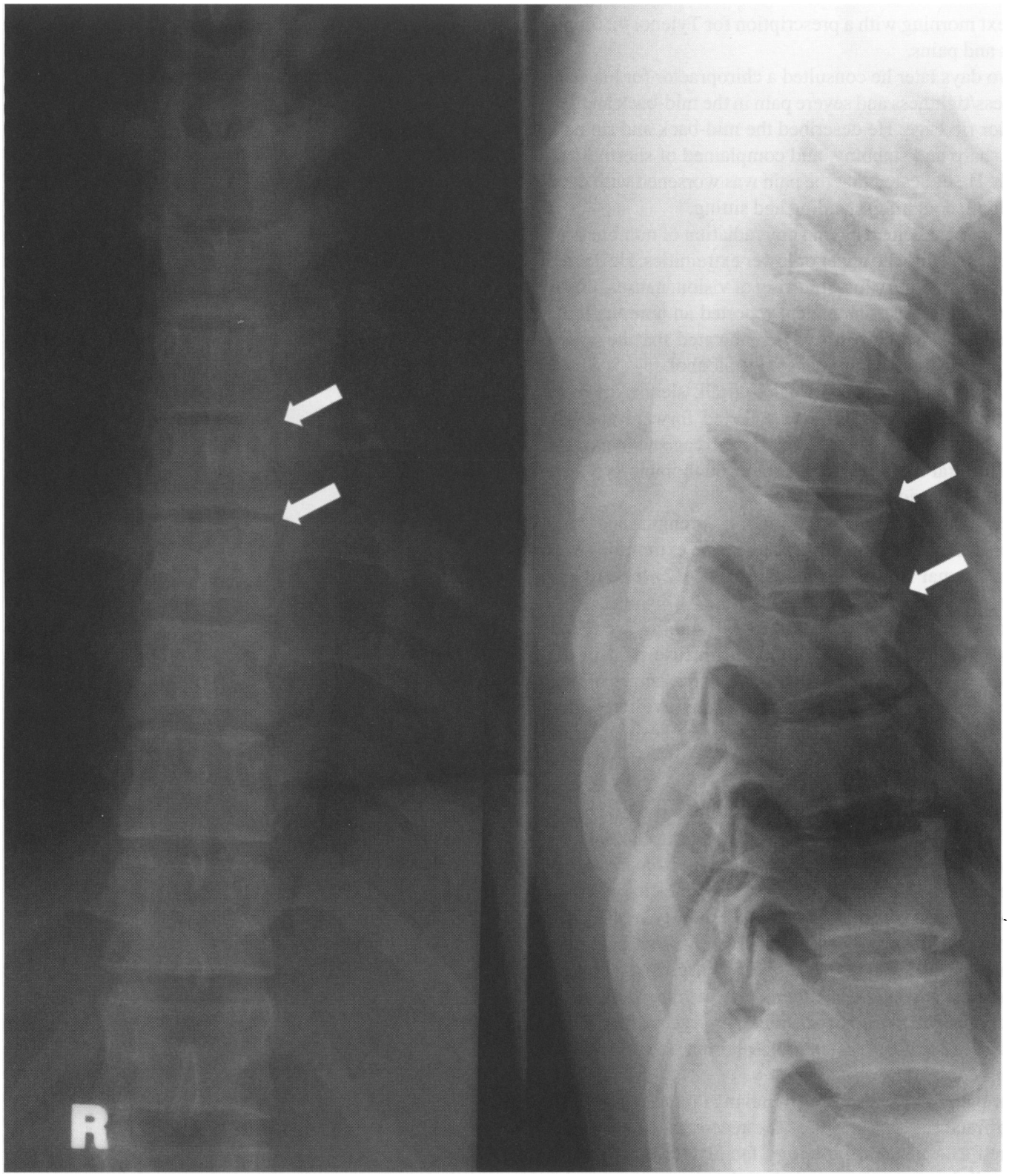

Figures 2a and 2b 3 months post-injury healing at T7 and T8.

focal gibbus deformity at this location. There was approximately 20% of anterior vertebral body height loss at T7 and at T8 with disruption of the superior end plates. The posterior vertebral height was well preserved with no widening of the interpediculate distance (See Figure 1).

The patient was diagnosed with mild thoracic (T7,T8) compression fractures, cervical and thoracic strain/sprain and left intercostal strain.

The patient was treated initially four times per week for four weeks. To provide pain relief, in the first two weeks treatment included electrotherapy (IFC) to the affected thoracic spine and left anterolateral rib cage, soft tissue therapy to the affected musculature and cervical spine mobilizations. Spinal manipulation is an absolute contraindication for acute compression fractures. Cryotherapy was recommended for home use.

After two weeks, a rehabilitation protocol was prescribed. The patient was instructed in postural exercises (including the use of a lumbar back support), neck stretches and range of motion exercises. The patient reported significant relief after three weeks of treatment. Due to his comfort level and motivation, the patient returned to his job which consisted mostly of computer work. He was advised to modify his activities (e.g.,) at work to avoid aggravating his condition and continue with his treatment. At four weeks, neck isometric exercises and cardiovascular conditioning (bike and treadmill) were added to the program.

A repeat x-ray was done one month post injury and it demonstrated persistent deformities of the T7 and T8 vertebral bodies with disruption of the end plates and anterior vertebral body loss by 20%. There was also slight sclerosis of the superior end plate of T8 consistent with healing.

At four weeks post-accident, the frequency of visits was decreased to two to three times per week for the next four to six weeks. At six weeks post-trauma, thoracic spine mobilizations and thoracic range of motion exercises were started. Progressive resisted neck exercises were also incorporated. The frequency was further reduced to once per week for six to eight weeks. Strengthening exercises for the thoracic spine using weights were prescribed. The patient was instructed to increase sets and repetitions gradually up to tolerance.

Towards the end of the plan of management, the patient was referred to an orthopedic surgeon for review and further recommendations. It was the opinion of the orthopedic surgeon that the fractures were healing well and since the patient was improving significantly he was advised to continue with his comprehensive self-directed exercise program.

A third set of radiographs was taken approximately three months post-injury and they revealed that healing of the deformities at T7 and T8 was visible (See Figures 2a and 2b).

Discussion

Spinal injuries in snowboarders, although not as common as upper and lower extremity injuries, have been cited in the literature.[1,5] Tarazi et al.[1] published incidence rates of spinal injuries among snowboarders to be 0.04 per 1000 snowboarder days. Gagnong et al.[2] reported injury patterns in 415 injured snowboarders and found that spinal fractures comprised 4.2% (8/187) of all reported fractures. Both studies found that spinal fractures occurred primarily in males (74–100%) and that the average age at the time of injury was early to mid-twenties. Intentional jumping resulting in falls was cited as the most common mechanism for spinal fractures.[1,2,6] The case outlined in this report fits the classic characteristics that are described in the literature.

In the general population, compression fractures account for approximately 47% of all spinal fractures.[7] In a ten-year retrospective study of all patients with traumatic spinal injuries involving levels T2–T10, Hanley and Eskay found that there was a peak in incidence of fractures of the apex of the anatomic kyphosis.[4] The most common levels of injury were T6–T8. The patient discussed in this report sustained compression fractures at the T7 and T8 spinal levels.

Denis developed a new biomechanical concept known as the three column spine to describe tissue failure in different types of spinal fractures.[7] This model proposed a third or middle column, which included the following structures: posterior longitudinal ligament, posterior annular fibrosus and the posterior wall of the vertebral body. Structures anterior and posterior to these made up the anterior and posterior columns, respectively.

According to Denis,[7] compression fractures involve failure of the anterior column only. The middle column is completely intact and if there is severe distraction than the posterior column may be involved. The undisturbed middle column is pathognomonic of compression fractures,

since it is involved in burst fractures, seat-belt type fractures and fracture-dislocations.[7]

The mechanism of anterior compression fractures, such as the one sustained by this patient, is anterior flexion and compression.[8] This patient also had the most common type of compression fracture, which involves failure of the upper end-plate of the vertebra in its anterior portion.[7]

Traumatic compression fractures are considered to be stable and not directly responsible of any acute neurological damage.[3,4,7] An exception to this may occur when loss of anterior body height exceeds 50%, progressive kyphosis and instability may ensue. This patient sustained approximately 20% loss of anterior vertebral body height and his condition was considered to be stable. However, repeat radiographs were done to monitor for any progression as well as healing.

Stable compression fractures are treated conservatively. Conservative care focuses on stabilization of the injured region, pain control, and promotion of soft tissue healing using passive treatment modalities.[9] Rehabilitation deals with restoration of musculoskeletal function in patients with subacute, chronic and recurrent conditions.[9] Rehabilitation is often introduced in the subacute phase. In this phase, passive modalities are weaned down and at the same time active components are introduced. With time the rehabilitation protocols (e.g., functional strengthening, stretching, cardiovascular fitness, balance and coordination) become the dominant component of the patient's management. The ultimate goal of rehabilitation is to prevent or manage disability through functional restoration, work hardening and psychosocial intervention.[9] The clinician should keep in mind that patients are unique individuals and some may progress quite quickly where as others may have barriers to recovery.

Rehabilitation protocols are based on fracture healing rate and patient tolerance.[9] The fracture healing process spans approximately four to six weeks in a young patient and six to twelve weeks in the geriatric patient.[10] In this case, the patient received passive conservative treatment only for two weeks. Since the patient's discomfort was decreased quickly and he was highly motivated, an active component was incorporated into his plan of management earlier than anticipated. The patient's progress was quite significant in a short amount of time and he returned to work (computer/desk job) three weeks following his initial presentation to the chiropractor.

To predict the long-term prognosis for patients who sustain wedge-shaped compression fractures is difficult for clinicians. Kerttula et al.[11] published a retrospective clinical and MRI study documenting the occurences of disc degeneration in the spines of young patients with a history of conservatively treated wedged compression fractures. They found a significant correlation between endplate injury in conjunction with wedged compression fractures and disc degeneration in patients greater than fifteen years of age. None of the patients who were less than 15-years-old with earlier vertebral fractures had degenerative discs. They explained this finding by the fact that there is a vascular network supplying blood to the cartilaginous endplates and the intervertebral discs until approximately twelve years of age.[11] To extrapolate this data to young adults, it is likely that our patient will go on to develop degenerative disc disease after his fractures heal.

Whether this condition will cause future back pain is a debatable issue, since degenerative changes of the intervertebral discs are common findings in symptomatic and asymptomatic people.[10] Kerttula et al.[11] found that only a minority of subjects with fractures had symptoms after a one-year follow-up.

Conclusion

Whenever significant trauma is involved, the clinician's index of suspicion must be heightened and fractures must always be suspected. Chiropractors use spinal manipulation as their primary mode of treatment. However, as evident in this case, this treatment modality is contraindicated in the fractured spine. A proper diagnosis is key, and the plan of management should reflect the concepts of conservative care and rehabilitative protocols.

References

1 Tarazi F, Dvorak M, Wing P. Spinal injuries in skiers and snowboarders. Am J Sports Medicine 1999; 27(2):177–180.

2 Ganong R., Heneveld E., Beranek S, Fry P. Snowboarding Injuries: a report on 415 patients. Physician and Sportsmedicine1992; 20(12):114–122.

3 Elattrache N, Fadale P. Thoracic spine fracture in a football player. Am J Sports Medicine 1993; 21(1):157–161.

4 Hanley E, Eskay M. Thoracic spine fractures. Orthopedics 1989; 12(5):689–696.

5 Pino EC, Colville MR. Snowboard injuries. Am J Sports Medicine 1989; 17(6):778–781.

6 Seino H, Kawaguchi S, Sekine M, Murakami T, Yamashita T. Traumatic paraplegia in snowboarders. Spine 2001; 26(11):1294–1297.
7 Denis F. The three column spine and its significance in the classification of acute thoracolumbar spinal injuries. Spine 1983; 8(8):817–831.
8 Clements D, Thiel H, Cassidy J, Mierau D. Fractures of the thoracolumbar spine: a report of three cases. J Can Chiropr Assoc 1991; 35(1):17–24.
9 Liebensen C. Integrating rehabilitation into chiropractor practice (blending active and passive care). Rehabilitation of the Spine. Liebensen C. ed. Williams and Wilkins, Baltimore, 1996:13–43.
10 Yochum T, Rowe L. Essentials of Skeletal Radiology. 2nd Ed. Baltimore: Williams and Wilkins,1996.
11 Kerttula L, Serlo W, Tervonen O, Paakko E, Vanharanta H. Post-traumatic findings of the spine after earlier vertebral fracture in young patients. Spine 2000; 25(9):1104–1108.